



P-ISSN: 2664-3685

E-ISSN: 2664-3693

IJPG 2021; 4(1): 01-03

Received: 19-10-2020

Accepted: 02-12-2020

Dr. Sirish Bhupathi

Resident, Department of Pediatrics, S.B.K.S MIRC Sumandeep Vidyapeeth Deemed to be University Pipariya, Vadodara, Gujarat, India

Dr. Manil Shah

Resident, Department of Pediatrics, S.B.K.S MIRC Sumandeep Vidyapeeth Deemed to be University Pipariya, Vadodara, Gujarat, India

Dr. Rinam Doshi

Resident, Department of Pediatrics, S.B.K.S MIRC Sumandeep Vidyapeeth Deemed to be University Pipariya, Vadodara, Gujarat, India

Corresponding Author:

Dr. Sirish Bhupathi

Resident, Department of Pediatrics, S.B.K.S MIRC Sumandeep Vidyapeeth Deemed to be University Pipariya, Vadodara, Gujarat, India

Congenital malaria due to *Plasmodium vivax* infection in a neonate

Dr. Sirish Bhupathi, Dr. Manil Shah and Dr. Rinam Doshi

DOI: <https://doi.org/10.33545/26643685.2021.v4.i1a.114>

Abstract

Introduction: Congenital malaria occurs through vertical transmission of parasites from mother during pregnancy/perinatally during labour. Presence of maternal antibody may delay symptoms upto 3-6 weeks after birth.

Case Representation: A 21days neonate presented with not accepting feed, excessive crying, fever since 2days. On examination baby was pale, lethargic, febrile, hepatosplenomegaly+. Peripheral smear-rings & trophozoits of *P. vivax*, diagnosed as congenital malaria with neonatal sepsis. IV. Ceftriaxone, IV. Amikacin started. Chloroquine was given.

Discussion: This case shows importance of considering congenital malaria as differential diagnosis of neonatal sepsis in neonates with history of malaria during pregnancy. Mechanisms for congenital transmission of malaria include maternal transfusion into fetal circulation at delivery/during pregnancy. Sometimes mother might had mild episode malarial during the 9th month of pregnancy, resolved spontaneously, and remained undiagnosed. The time of onset of symptoms in congenital malaria can vary from immediately after birth to few weeks. The drug of choice for congenital malaria remains chloroquine.

Keywords: Congenital, neonate, malaria, sepsis, transperantal, transmission

1. Introduction

Congenital malaria was first described in 1876 [1]. Congenital malaria, occurring as a result of vertical transmission of parasites from mother to child during pregnancy or perinatally during labour is a rare condition. It occurs as a consequence of clinical attacks of malaria during pregnancy but also may be detected rarely in infants of asymptomatic women, where the diagnosis may be missed in both mother and the neonate [2]. However, recently the incidence of congenital malaria is on the rise due to increased resistance and virulence of parasite resulting from altered antigenic determinants, in addition to increased awareness [3]. Malarial infection of placenta is characterized by syncytiotrophoblast and villous disruption, syncytial knot formation and fibrin-type fibrinoid deposition. Syncytial destruction may result in low birth weight and congenital infections [4]. Hence, malaria during pregnancy may cause two extreme effects on the neonatal outcome. Presence of maternal antibody may delay the onset of symptoms up to 3 to 6 weeks after birth. Past history and relevant investigations of the mother may help in differentiation from vector borne malaria in infants in these situations.

2. Case details: A 21days old female neonate was brought to our NICU with complaints of not accepting feed, excessive crying, fever since 2 days. On examination baby was pale, lethargic, axillary temperature was 100.8°F, palpable liver - 2cms, spleen - 4cms below right and left subcostal margins respectively.

On based on clinical and laboratory findings, differential diagnoses of Congenital Malaria and Neonatal Sepsis were considered. Antibiotic consisting of intravenous Ceftriaxone and Amikacin were started. After reports Antibiotics were discontinued and antimalarial therapy with Chloroquine base -10mg /kg followed by 5mg /kg at 6, 24, 48 hrs were given. Gradually clinical condition improved, patient was afebrile after starting antimalarials and spleen size reduced to normal over 7 days duration. Three days after treatment, the patient's parasitemia completely cleared on peripheral blood smear. The infant was discharged on DOL-28. In view of the revised diagnosis, the history of the mother was re-evaluated; A history of low grade fever at ninth month of pregnancy was present, and took local home

medicine for 1 day; presently post delivery she had high grade fever with chills, so went to local hospital and

underwent blood investigation and informed as malaria positive and she took 3 days oral medication for the same.

Table 1: Investigation on admission and on discharge

Reports	On admission	On discharge
Hb	7.2 gm/dL	7.4 gm/dl
TLC	12,200 cells/cumm	12500 cells/cumm
DC polymorphs / leucocytes / monocytes	22 / 74 / 2 / 2	22 / 70 / 4 / 4
Platelets	100,000 cells/cumm	337,000cells/cumm
CRP	212.58 mg/dL	8.5mg/dL
Total bilirubin	4.2 mg/dL	
Blood culture	Sterile	
CSF culture	Sterile	
Urine culture	Sterile	
Peripheral smear	Rings & Trophozoites of <i>plasmodium vivax</i>	No parasites

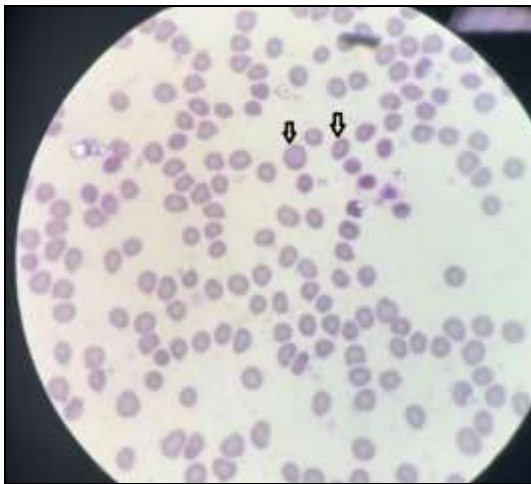


Fig 1: Rings of *P. Vivax*

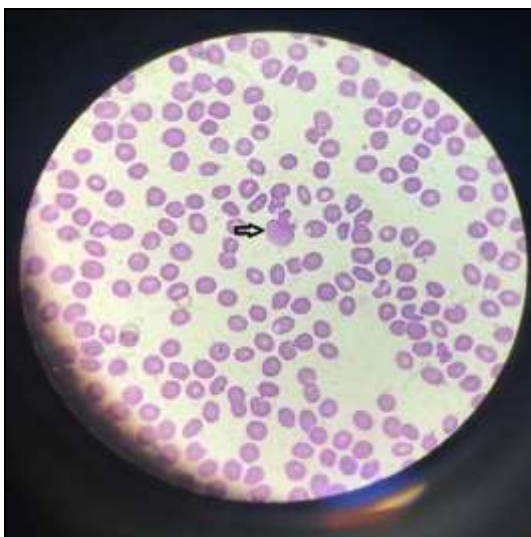


Fig 2: Trophozoites of *P. vivax*

3. Discussion

Malaria in pregnancy and newborn causes significant burden of disease, and estimated to cause more than 300,000 fetal and infant deaths and 2,500 deaths of pregnant women worldwide annually [5]. Congenital malaria, occurring as a result of vertical transmission of parasites from mother to child during pregnancy/perinatally during labour is a rare clinical condition. Malarial infection of placenta leads to syncytial destruction which may result in low birth weight, premature labour, intrauterine growth retardation, high

perinatal mortality, anemia, miscarriage and congenital infections [4]. Though some authors describe the occurrence of congenital malaria in new-borns aged less than 7 days, the interval between birth and onset of symptoms may be prolonged. This can be explained by transmission of infection in late pregnancy / during delivery / by presence of trans placentally acquired maternal antibody (IgG). Transfer of protective immunity is the main factors that affects the age of symptom onset. Available literature usually describes the onset of symptoms of congenital malaria typically between 3 to 12 weeks after birth, coinciding with the half-life of maternal IgG antibody in infants [6]. Hence, neonates with congenital malaria are usually healthy at birth, and symptoms appear when the level of passively acquired maternal antibodies starts to wane. Congenital malaria may be detected rarely in infants of asymptomatic women [5]. CRP level was elevated. Increased CRP is seen in infectious and inflammatory conditions, tissue necrosis and apoptosis. It also has been reported to rise in malarial infection [7]. In our patient the diagnosis of congenital malaria in the patient at the age of 21 days was made by the presence of rings and trophozoites of *P. vivax* in peripheral smear, and positive rapid malaria test. The treatment of neonatal *vivax* malaria comprises of a blood schizonticide, like chloroquine. Primaquine is not given in congenital malaria as there is no exoerythrocytic stage of the parasite [5]. The clinical features of neonatal malaria include anaemia (77%), fever (74%), liver and spleen enlargement (68%), poor feeding/lethargy/irritability and jaundice [10, 12]. Severe thrombocytopenia without bleeding, is also a frequently reported feature of congenital malaria [8, 9, 10].

Fever may be occasionally absent, and accompanying features which need to be examined include irritability, hepatosplenomegaly, anorexia, haemolytic anaemia, jaundice and thrombocytopenia. This case suggests that the diagnosis of congenital malaria should be considered as an important differential diagnosis of neonatal infections and sepsis in malaria endemic countries with or without an obvious well recollected history of malaria during pregnancy [7].

4. Conclusion

1. Congenital malaria should be considered as an important differential diagnosis of neonatal infections and sepsis in malaria endemic countries.
2. Early diagnosis could prevent antibiotics usage and could prevent neonatal mortality

5. References

1. Romand S, Boure'e P, Gelez J, Bader-Meunier B, Bisaro F, Dommergues JP, *et al.* Congenital malaria. A case observed in twins born to an asymptomatic mother. *Presse Med* 1994;23:797-800
2. Davies HD, Keystone J, Lester ML, Gold R. Congenital malaria in infants of asymptomatic women. *Can Med Assoc J* 1992;146:1755-1756.
3. Valecha N, Bhatia S, Mehta S, Biswas S, Dash AP. Congenital malaria with atypical presentation: a case report from low transmission area in India. *Malaria J* 2007;6:43.
4. Crocker IP, Tanner OM, Myers JE, Bulmer JN, Walraven G, Baker PN, *et al.* Syncytiotrophoblast degradation and the pathophysiology of the malaria-infected placenta. *Placenta* 2004;25:273-282.
5. Menendez C, D'alessandro U, Ter Kuile FO. Reducing the burden of malaria in pregnancy by preventive strategies. *Lancet Infect Dis* 2007;7:126-135.
6. Quinn TC, Jacobs RF, Mertz GJ, Hook EW III, Locklsey RM. Congenital malaria a report of four cases and a review. *J Pediatr* 1982;101:229-232.
7. Gillespie SH, Dow C, Raynes JG, Behrens RH, Chiodini PL, McAdam KP, *et al.* Measurement of acute phase proteins for assessing severity of *Plasmodium falciparum* malaria. *J Clin Pathol* 1991;44:228-231
8. Voittier G, Arsac M, Farnoux C, Mariani-Kurdjian P, Baud O, Aujard Y, *et al.* Congenital malaria in neonates: two case report and review of literature. *Paediatrica* 2008;97:500-512.
9. Lesko CR, Arguin PM, Newman RD. Congenital malaria in the United States. *Arch Pediatr Adolesc Med* 2007;161:1062-1067.
10. Baspinar O, Bayraktaroglu Z, Karsligil T, Bayram A, Coscun Y. A rare case of anemia and thrombocytopenia in a newborn: congenital malaria. *Turk Journ Pediatr* 2006;48:63-658.